

# First detection of spring viraemia of carp virus in common carp (*Cyprinus carpio* L.) affected by a septicæmic disease in Mexico

Cesar Ortega<sup>1</sup>  | Leticia Cañas-Lopez<sup>1</sup> | Rute Irgang<sup>2,3</sup> | Raúl Fajardo<sup>1</sup> |  
Matías Poblete-Morales<sup>2,3</sup> | Benjamin Valladares-Carranza<sup>1</sup> | Diana Tapia-Cammas<sup>2,3</sup> |  
Ruben Avendaño-Herrera<sup>2,3,4</sup> 

<sup>1</sup>Centro de Investigación y Estudios Avanzados en Salud Animal (CIESA), Facultad de Medicina Veterinaria y Zootecnia, Universidad Autónoma del Estado de México, Toluca, México

<sup>2</sup>Laboratorio de Patología de Organismos Acuáticos y Biotecnología Acuicola, Facultad de Ciencias de la Vida, Universidad Andrés Bello, Viña del Mar, Chile

<sup>3</sup>Centro FONDAP, Interdisciplinary Center for Aquaculture Research (INCAR), Viña del Mar, Chile

<sup>4</sup>Centro de Investigación Marina Quintay (CIMARQ), Universidad Andrés Bello, Quintay, Chile

## Correspondence

Ruben Avendaño-Herrera, Laboratorio de Patología de Organismos Acuáticos y Biotecnología Acuicola, Facultad de Ciencias Biológicas, Universidad Andrés Bello, Viña del Mar, Chile.

Emails: ravendano@unab.cl; reavendano@yahoo.com

and  
Cesar Ortega, CIESA, Facultad de Medicina Veterinaria y Zootecnia, Universidad Autónoma del Estado de México, Toluca, Mexico.

Emails: cos\_mx@hotmail.com; cortegas@uaemex.mx

## Funding information

Comisión Nacional de Investigación Científica y Tecnológica, Grant/Award Number: FONDAP 15110027 and FONDECYT 1150695; Consejo Nacional de Ciencia y Tecnología, Grant/Award Number: 287537 and 4489/2018/CI; Secretaria de Investigación y Estudios Avanzados (SIEA), Universidad Autónoma del Estado de México (UAEM)

## Abstract

Spring viraemia of carp (SVC) is an infectious disease responsible for severe economic losses for various cyprinid species, particularly common carp (*Cyprinus carpio carpio*). The causative agent is the SVC virus (SVCV), a member of the *Sprivirus* genus, *Rhabdoviridae* family, and a List 1 pathogen notifiable by the World Organization for Animal Health. This study describes the diagnosis of an SVCV pathogen isolated in October 2015 from wild common carp inhabiting a natural lagoon in central Mexico. While neither an epidemic nor fish mortalities were reported, the collected killed specimens exhibited clinical signs of disease (e.g., exophthalmia, moderate abdominal distension and haemorrhaging, as well as internal haemorrhages and adhesions). Histological results of injuries were consistent with the pathology caused by SVCV. This finding was supported by the isolation of a virus in EPC and BF-2 cells and subsequent RT-PCR confirmation of SVCV. The phylogenetic analyses of partial SVCV glycoprotein gene sequences classified the isolates into the Ia genogroup. These findings make this the first report of SVCV detection in Mexico, extending the southern geographical range of SVCV within North America. However, since this pathogen was detected in fish inhabiting a natural body of water without tributaries or effluents, it is difficult to estimate the risk of SVCV for other wild/feral cohabiting cyprinid species in the lagoon. The status of this virus is also unknown for other bodies of water within this region.

## KEYWORDS

*Cyprinus carpio*, México, spring viraemia of carp virus

## 1 | INTRODUCTION

The common carp (*Cyprinus carpio* L) is a freshwater and brackish fish originated in Asia and has been farmed in China since at least 475 BC. Due to its ability to tolerate eutrophic waters and adverse environmental conditions, carp are farmed across a wide range of geographical and climatic areas worldwide (FAO, 2018). The common carp was introduced to Mexico from Asia in 1889 (Wakida-Kusunoki & Amador-del-Ángel, 2011) and is now distributed across the country, with the purpose of providing animal protein to rural populations and additional work opportunities to the community (Wakida-Kusunoki & Amador-del-Ángel, 2011). In 2017, carp production reached 53,421 tons, reflecting an annual estimated growth of 7.43% (CONAPESCA, 2017).

Despite resilience to a wide range of environmental, climatic and geographical conditions, carp are susceptible to a variety of infectious diseases. Primary among these diseases is the spring viraemia of carp virus (SVCV), a notifiable pathogen according to the World Organization for Animal Health (OIE, 2017a) and a virus responsible for mortalities associated with acute haemorrhaging. To date, SVCV has been reported in common carp and other freshwater cyprinids in Asia and Europe, while detection on the American continent has been reported in the United States, Canada (Ahne et al., 2002; Ashraf et al., 2016; Garver et al., 2007; Goodwin, 2011) and Brazil (Alexandrino, Ranzani-Paiva, & Romano, 1998; OIE, 2017a). Nevertheless, SVCV has not yet been detected in Mexico.

SVCV, the type species of the *Spriovivirus* genus and member of the Rhabdoviridae family (Afonso et al., 2016; ICTV, 2017; OIE, 2017a), exhibits a genome structure that includes five genes encoded in the order 3-N-P-M-G-L-5, representing the nucleocapsid, phosphoprotein, matrix protein, glycoprotein and polymerase protein genes, respectively. SVCV infects different carp species, as well as other cyprinids and ictalurids (Ashraf et al., 2016), and poses sanitary concerns in the global aquaculture industry. Other aquatic rhabdoviruses are also a threat to wild and farmed fish species. These include the viral haemorrhagic septicaemia virus (VHSV) and the infectious haematopoietic necrosis virus (IHNV) of the *Novirhabdovirus* genus, both of which are also listed as notifiable aquatic animal diseases by the OIE (2017a).

In Mexico, sanitary control measures associated with diseases in farmed carp are scarce, especially in relation to viral agents. López-Jiménez (1987) reported on the occurrence of non-published cases of infectious ascites attributed to bacterial infections of *Aeromonas* spp. and *Pseudomonas* spp., whereas the occurrence of viral cases was largely ruled out, excepting one case in which coronavirus-like viral particles were microscopically identified. In turn, Vélez-Hernández, Constantino-Casas, García-Márquez, and Osorio-Sarabia (1998) reported cases of *Centrocestus formosanus* parasite infections in wild carp, and Soriano-Vargas, Castro-Escarpulli, Aguilera-Arreola, Castro-Escarpulli, Aguilera-Arreola, Vega-Castillo, and Salgado-Miranda (2010) reported the occurrence of septicaemia caused by *Aeromonas bestiarum* in common carp from central

Mexico. The present study describes a case of septicaemic disease in wild common carp obtained from a lagoon without tributaries or effluents in central Mexico. Tissue samples collected from fish exhibiting clinical signs were analysed via cell cultures, molecular techniques, gene sequencing and electronic microscopy, ultimately resulting in the isolation and identification of a rhabdovirus with traits similar to SVCV.

## 2 | MATERIAL AND METHODS

### 2.1 | Fish sampling

In October 2015, a total of 10 wild common carp (*C. carpio*) were collected as the result of a health-monitoring programme for fish in central Mexico. The collected carp were delivered alive within 24 hr of collection to the Aquatic Animal Health Laboratory (Facultad de Medicina Veterinaria y Zootecnia, Universidad Autónoma del Estado de México, Toluca, México).

All 10 specimens were collected from Tecocomulco, a natural freshwater lagoon in the state of Hidalgo that is approximately 1,769 hectares in size and without tributaries or effluents (Rico-Sánchez, Rodríguez-Romero, López-López, & Sedeño-Díaz, 2014). The lagoon is formed by run-off and springs from the surrounding mountains, has an average length of 10.5 km, is between 1.0 and 3.5 km wide and has a depth, depending on periods of drought, between 70 cm and 2 m (Novelo, Montejano, Cantoral, & Tavera, 2005). No disease outbreaks and/or disease-related mortalities have been reported for the lagoon for any of the different fish populations. Common carp ( $\approx 250$  g) were captured using a net that traps the fish through the gills. Many of the collected fish presented signs of septicaemic disease, characterized by moderate exophthalmia, abdominal distension and haemorrhaging in the ventral and lateral areas, as well as at the base of the fins.

### 2.2 | Macroscopic, histological and microbiological analyses

All fish were killed via anaesthetic overdose (240 mg/L tricaine methanesulfonate 222; Sigma) and immediately subjected to post-mortem examination. Initial external observations were conducted, and the lesions of each specimen were recorded. Examinations were then conducted for the presence of external parasites, and scrapings were obtained from gills and skin for microscopic observation at 10 $\times$  and 40 $\times$  magnifications. In addition, the microscope slides were Gram-stained.

For histological analyses, internal samples were taken from each fish, fixed in vials containing 10% buffered formalin, dehydrated and embedded in paraffin wax following standard procedures. Each tissue was sectioned at 5  $\mu$ m and stained with haematoxylin and eosin to describe histopathological alterations, as in Ortega et al. (2016). Sections were observed at different magnifications under an Olympus BH-2 light microscope.

The aspect, colour and contents of the body cavity were also reviewed. Samples for bacterial isolation were aseptically taken from external skin lesions, the kidney, spleen, liver and brain of each specimen and streaked onto tryptone soy agar (TSA; Oxoid) and Columbia sheep blood agar (AES Laboratoire, France). All plates were aerobically incubated at 28°C and examined every 24 hr for 7 days. If no colony growth was observed after a week, the cultures were considered negative.

### 2.3 | Virus isolation from cell cultures

The clinical signs presented by the collected carp led to the presumption that an agent similar to SVCV could be responsible. To explore this possibility, the diagnostic procedures suggested by the OIE (2017b) for virus isolation were followed, with kidney and spleen samples collected from fish with haemorrhagic injuries and internal adhesions. Portions of these tissues were pooled in two 15-ml Falcon tubes containing 9 ml of Leibovitz's L-15 Medium (Gibco BRL), coded as Carp-1 (composed with kidney and spleen samples collected from two fish specimens) and Carp-2 (composed with three other fish). Each sample macerated and centrifuged at 4,000 g for 15 min at 4°C. The obtained supernatant was recovered and filtered at 0.22 µm. Each sample was diluted to 1:10 and 1:100 and inoculated, in duplicate, at a ≥90% confluence in 12-well multiwell plates containing cell monolayers of Epithelioma Papulosum Cyprini (EPC) and bluegill fry (*Lepomis macrochirus*, BF-2), which were respectively incubated at 20°C and 25°C. The inoculated cells were examined daily under an inverted Axiovert 40 C/40 CFL, ZEISS® microscope to establish the presence of the cytopathic effect (CPE). The supernatants of plates evidencing a positive CPE were recovered and again inoculated and incubated as previously described. Multiwell plates with EPC and BF-2 were incubated at 25°C. Negative controls consisted of duplicate sets of wells containing monolayers of the respective cell lines. These monolayers were inoculated with 0.1 ml of filter-sterilized (0.45 µm pore diameter) Hanks' balanced salt solution. The lack of SVCV reference material precluded the use of a positive control. Cultures that did not exhibit a positive CPE were blind-passed at least once before being classified as negative.

### 2.4 | Electron microscopy

Electron microscopy was carried out on EPC monolayers grown in 6-well tissue culture plates. The cells were inoculated with supernatants from CPE-positive cultures of Carp-1 and Carp-2. At 48 hr post-inoculation, the cell culture medium was removed. The monolayers were harvested by scraping, centrifuged for 1 hr at 500 g, fixed in glutaraldehyde (2.5% in 0.1 M sodium cacodylate buffer, pH 7.4) and post-fixed in 2% osmium tetroxide for 1 hr. Cells were dehydrated with ascending concentrations of acetone and then embedded in epoxy resin (Epon 812; Electron Microscopy Sciences) and acetone. Semi-fine slices (150 µm) were obtained using an ultramicrotome and were mounted on slides contrasted with toluidine blue (Electron Microscopy Sciences).

Once the area of interest was identified, fine slices (80 µm) were obtained and mounted on copper grids contrasted with uranyl acetate and lead citrate (Electron Microscopy Sciences). Finally, samples were observed using a Jeol 1010 electron transmission microscope at 60 kV.

### 2.5 | RNA extraction and reverse-transcription polymerase chain reaction (RT-PCR)

Cell cultures were collected for virus identification when CPE appeared, usually 2–4 days post-inoculation. Total RNA was extracted from the supernatant of EPC cell cultures (200 µl) using the TRIzol Reagent (Life Technology, USA) following the manufacturer's instructions. Then, cDNA was synthesized through reverse transcription using the commercial PrimeScript™ RT Reagent Kit, with gDNA Eraser (Perfect Real Time, TAKARA, Japan) added for each 1 ng reaction of total RNA in a final reaction volume of 20 µl.

Molecular diagnosis of SVCV was performed following recommendations in the Manual of Diagnostic Tests for Aquatic Animals (OIE, 2017b), as based on Stone et al. (2003). The GoTaq® Flexi DNA Polymerase (Promega, USA), which contains all of the elements needed for the reaction, was used with a final volume of 25 µl and using 200 ng of cDNA as a template. The employed primers (SVCV-F1 and SVCV-R2) amplified a 714-bp fragment corresponding to part of the coding sequence for the glycoprotein gene of putative SVCV. The amplified product was then assessed through semi-nested PCR designed to amplify a 606-bp product (primers: SVCV-F1 and SVCV-R4). The amplification procedure for both protocols adhered to those described by Stone et al. (2003). All PCR amplifications were carried out in a G-storm Thermal Cycler T Gradients and were separated by electrophoresis on 1.5% (w/v) agarose gel, visualized with 1/10,000 GelRed Nucleic Acid Gel Staining (Biotium) and photographed under UV light. A GeneRuler 100 bp Plus DNA Ladder (Thermo Scientific) was employed as a molecular mass marker. A sample was considered positive if the expected sizes of the primary and secondary PCR products were 714 and 606 bp, respectively.

### 2.6 | Sequencing and phylogenetic analyses

Secondary amplification products were purified using the Wizard® SV Gel and PCR Clean-Up System Kits (Promega). Products were then sequenced by Macrogen Inc. (Korea). The sequences of the 560-bp region of Mexican isolates were analysed using the Basic Local Alignment Search Tool (BLAST) in NCBI ([http://blast.ncbi.nlm.nih.gov/Blast.cgi#alnHdr\\_57232119](http://blast.ncbi.nlm.nih.gov/Blast.cgi#alnHdr_57232119)). Alignments were performed with the ClustalW algorithm against phylogenetically related organisms available in the GenBank database. The genetic distance analyses were performed using Kimura's two-parameter model, and evolutionary trees were constructed using the neighbour-joining method with MEGA 7.0 (Kumar, Stecher & Tamura 2016). Bootstrap values were obtained from 1,000 replicates. The two obtained nucleotide sequences (coded Carp-1 and Carp-2) were deposited with the GenBank accession numbers MH569093 and MH569094.

### 3 | RESULTS

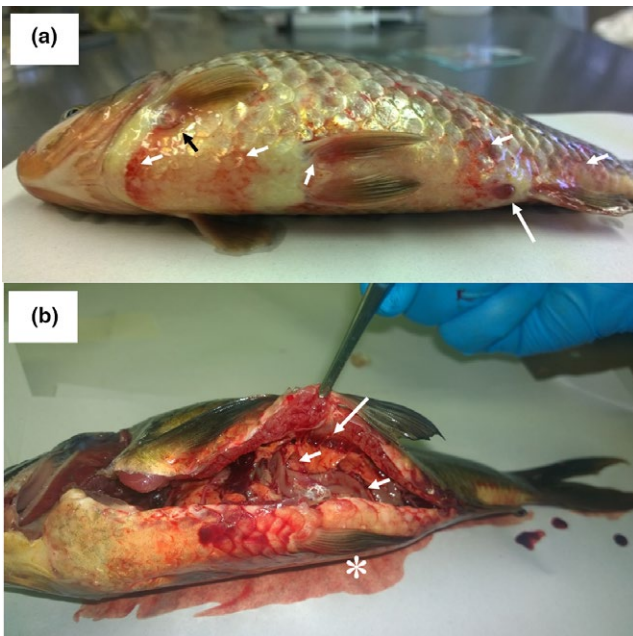
Macroscopic analysis demonstrated that 5 of 10 collected common-carp specimens presented clinical signs of exophthalmia, moderate abdominal distension and haemorrhages at the base of the pectoral and pelvic fins in lateral areas (Figure 1a). Internally, five fish presented sero-haemorrhagic ascites and the formation of adhesions between abdominal organs, and three fish manifested diffuse haemorrhages in the coelomic cavity, splenomegaly, congestion of the swim bladder, renomegaly and renal congestion (Figure 1b). Some fish presented scale loss and haemorrhages inside the mouth and on the lower jaw (data not shown).

Parasitological analysis revealed the presence of *Trichodina* sp. on the skin and gills and *Gyrodactylus* spp. on only the skin of 10 fish (data not shown). No parasitic agents were found in internal organs, and bacterial growth was not obtained for any of the sampled internal organs or for the ascetic liquid of fish with haemorrhages independent of the culture medium used. Likewise, Gram-stained imprints of these tissues did not reveal any bacterial presence. Histologically, the liver of affected fish presented perivascular haemorrhages (Figure 2a) with lymphatic degeneration and infiltration in the vascular walls, multifocal mononuclear hepatitis, hyperaemia with multiple areas of degeneration and necrosis, lymphocytic pancreatitis, necrosis and periacinar lymphocytic infiltration (Figure 2b). The kidney evidenced haemorrhagic and interstitial mononuclear nephritis, renal congestion, tubular dilation with proteinuria (Figure 2c), perirenal haemorrhagic cystitis, tubular degeneration with obstruction, and melanomacrophage proliferation (data

not shown). The spleen presented congestion and reticuloendothelial hyperplasia (Figure 2d) and melanomacrophage proliferation. The intestine showed perivascular inflammation and necrotic enteritis, with necrotic cryptitis of enterocytes and epithelial cells in the lamina propria (Figure 2e). Finally, epithelial scaling, villous atrophy and granulomatous ulcerative colitis were recorded (Figure 2f).

The two kidney and spleen homogenates (Carp-1 and Carp-2) of affected fish showed a CPE between 24 and 48 hr post-inoculation in EPC cell cultures, and 72 hr post-inoculation in BF-2 cell cultures. These results suggest that the clinical signs of disease observed in the common-carp specimens were caused by a viral agent. This hypothesis was confirmed via electron microscopy, which revealed an abundance of characteristic bullet-shaped viral particles with structural traits typical of rhabdovirus (110–123 nm long, 75.5–78.1 nm wide; Figure 3).

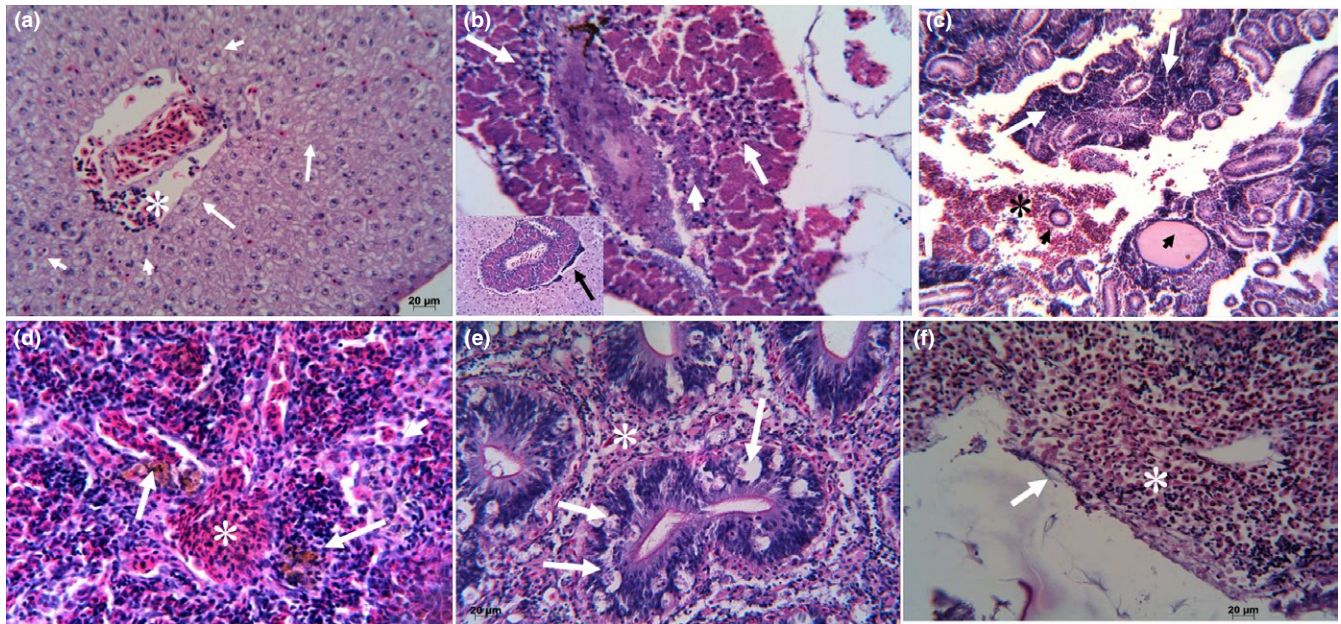
RT-PCR analyses conducted using the total extracted RNA from EPC and BF-2 cell cultures resulted positive for putative SVCV, independent of the cell line employed for viral isolation. The expected specific amplification product for SVCV was observed, with a size of 716 bp for the first reaction and of 606 bp for the second round. No product was generated with the negative control (Figure 4). The two amplification products were sequenced separately, in duplicate, and in both directions by Macrogen Inc. (Korea). This resulted in contigs with reads averaging  $702 \pm 12$  and  $573 \pm 5$  bp, showing that Carp-1 and Carp-2 were 100% similar. Both primers were removed, and a comparative analysis was performed against a partial sequence (560 bp) deposited in GenBank, the results of which revealed 99% identity with the SVCV glycoprotein of an isolated from Missouri, USA (DQ227504). Based on the phylogenetic analysis of partial SVCV glycoprotein gene sequences, the Carp-1 and Carp-2 isolates were classified into the Ia genogroup, closely related to the American and Chinese isolates (Figure 5).



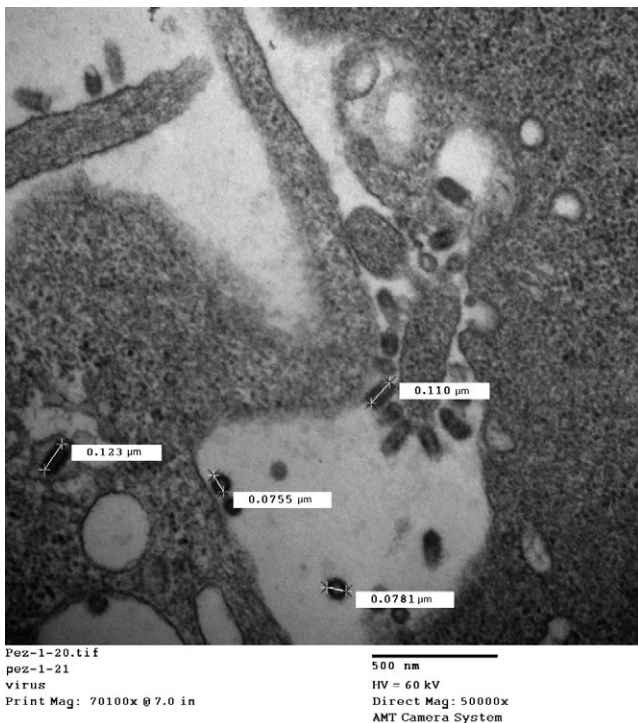
**FIGURE 1** Adult common carp affected by a septicemic disease caused by an SVCV pathogen. (a) External injuries: exophthalmia, inflammation of the anal orifice, and haemorrhages at the base of the fins and ventral/lateral areas; and (b) internal injuries: haemorrhagic ascites (asterisk), adhesions (arrow) and diffuse haemorrhages in organs of the coelomic cavity (arrowhead)

### 4 | DISCUSSION

This report describes an SVCV rhabdovirus as the cause of an infective outbreak among wild common carp in Mexico. While SVCV can replicate in fish, bird and mammalian cell cultures, optimal cell systems are those derived from cyprinid fish, such as EPC (Fijan et al., 1983), which grows at 20–22°C. The CPE of SVCV is characterized by a margination of nuclear chromatin followed by a rounding up, detachment and lysis of cells. The presently obtained results are consistent with these descriptions. However, given that SVCV is closely related to the pike fry rhabdovirus, an SVCV-specific RT-PCR was used to obtain a more precise identification (Stone et al., 2003). The second round of the semi-nested PCR protocol amplified a prominent 606-bp product corresponding to nucleotides 373–978 of the SVCV glycoprotein. Genetic clustering and geographical origin are closely linked for SVCV strains, which can be divided into the Asian and European clades (Miller et al., 2007; Stone et al., 2003). Phylogenetic analysis of the partial glycoprotein genes obtained for the SVCV isolates (Carp-1 and Carp-2)



**FIGURE 2** Histological injuries in common carp affected by an SVCV pathogen. (a) Liver with perivascular haemorrhaging (asterisk), hepatic degeneration represented by karyolysis (arrow) and pyknosis (arrowhead); (b) lymphocytic pancreatitis (arrows), necrosis (arrowhead) and periacinar lymphocytic infiltration (inset); (c) kidney with haemorrhagic (asterisk) and interstitial mononuclear (arrow) nephritis, as well as tubular dilation with proteinuria (arrowhead); (d) splenic congestion (asterisk) and reticuloendothelial hyperplasia (arrowhead), as well as multifocal haemosiderosis (arrow); (e) interstitial enteritis (lamina propria; asterisk) and necrotic cryptitis (arrow) with epithelial necrosis; and (f) epithelial scaling and villous atrophy (arrow), as well as granulomatous ulcerative colitis (asterisk)

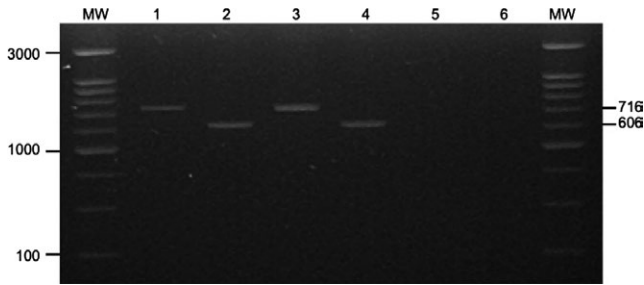


**FIGURE 3** EPC cells 3 days after inoculation with supernatants of common-carp tissues infected by an SVCV pathogen. Shown is the budding of viral particles with complete and transverse positioning, showing the typical bullet shape of rhabdovirus. Magnification  $\times 50,000$

resulted in placement into the Ia genogroup, closely related to the American isolates (Figure 5).

Spring viraemia of carp virus is an OIE-notifiable finfish rhabdovirus of major economic importance (OIE, 2017a). Unfortunately, the SVCV pathogen obtained from Mexican common carp was not confirmed by an international reference laboratory, nor has detection been reported to the OIE. Nevertheless, the Mexican sanitary authorities (National Service of Health, Safety, and Agroalimentary Quality SENASICA, Spanish acronym) have been duly informed. SVCV can be particularly devastating for the carp aquaculture industry and has also been reported to infect other commercially important species, including sheatfish (*Silurus glanis*), European perch (*Perca fluviatilis*), goldfish (*Carassius* spp.), zebrafish (*Danio rerio*), rainbow trout (*Oncorhynchus mykiss*) and tilapia (*Sarotherodon niloticus*) (OIE, 2017a). In addition to distinct varieties of carp, other aquaculture species farmed in Mexico could be impacted by SVCV (including rainbow trout and tilapia [CONAPESCA, 2017], as well as ornamental fish such as goldfish, zebrafish and other cyprinids). Such impacts can include death, as has been reported by Haghighi-Khiabani Asl, Bandehpour, Bandehpour, Sharifnia, and Kazemi (2008), who detected a molecularly uncharacterized SVCV-like virus responsible for mortalities in adult rainbow trout. Likewise, tilapia, zebrafish and even trout could act as carriers of this viral agent (Emmenegger et al., 2016; OIE, 2017b).

Spring viraemia of carp virus replicates in endothelial cells and leads to the perivasculitis, degeneration and, ultimately, necrosis of blood cells, which manifests as disseminated haemorrhages

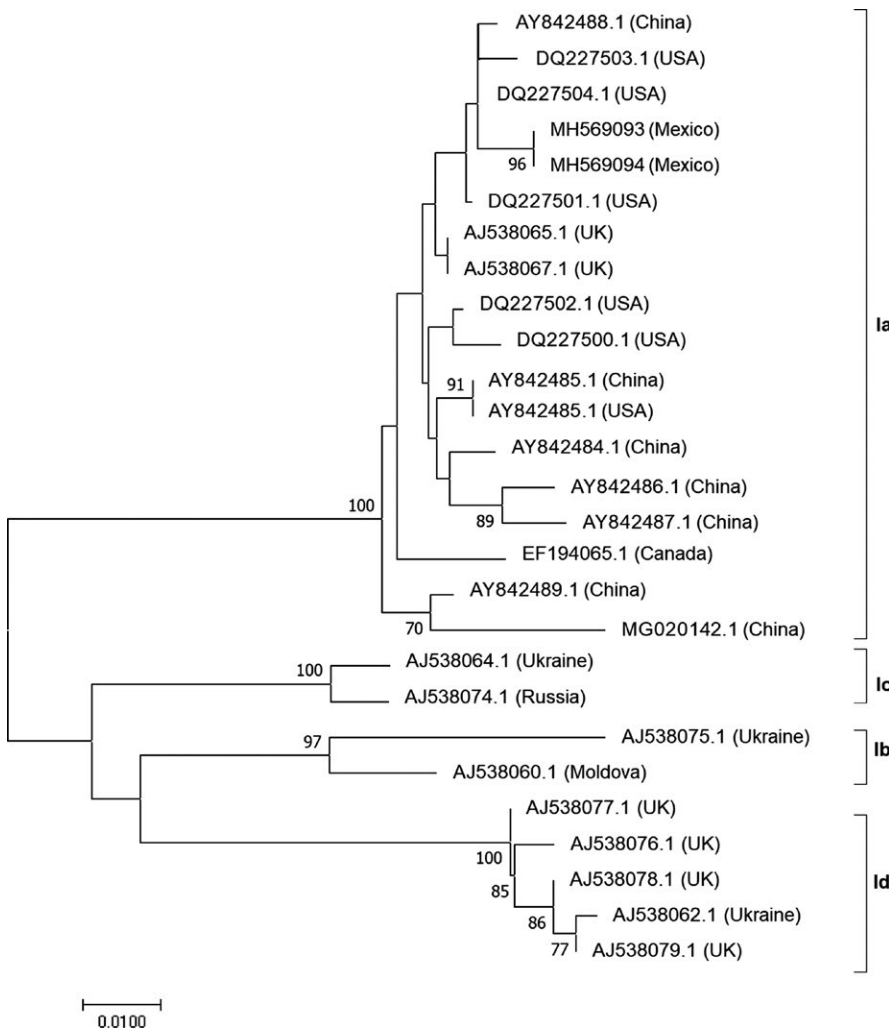


**FIGURE 4** Electrophoresis of the SVCV glycoprotein gene amplified by RT-PCR. MW: Thermo Scientific GeneRuler 100 bp Plus DNA Ladder. Lanes 1, 3 and 5: first-round PCR product (714 bp); lanes 2, 4 and 6: second-round PCR product (606 bp). Lanes 1 and 2 correspond to samples of the EPC cell culture supernatant with Carp-1; lanes 2 and 3 correspond to samples with Carp-2; and lanes 4 and 5 are negative controls (i.e., no fragment)

(Ahne et al., 2002). Death from a loss of sodium–water balance is primarily caused by damaged haematopoietic and kidney tissues (Gaafar et al., 2011). In the current study, only five of the 10 analysed fish showed clinical signs typical of an SVCV infection; besides external and internal haemorrhages, the sampled fish also showed histological injuries in various tissues. While such injuries are not

pathognomonic of SVCV, they are in line with descriptions in preliminary studies (Ahne et al., 2002; Gaafar et al., 2011; Negele, 1977). Surprisingly, however, no signs of disease or fish mortalities have been previously described for the Tecocomulco Lagoon, a situation that is difficult to explain or justify. It is important to note that while this lagoon is rurally located, it is visited by carp fishermen and tourists or weekend visitors. The Tecocomulco Lagoon is also host to several other species, including fish, such as charal (*Chirostoma* sp.), carps (*Cyprinus* spp., *Ctenopharyngodon idella*, *Hypophthalmichthys molitrix*, *Amblycephala megalobrema*, *Mylopharyngodon piceus*) and goldfish; amphibians, such as axolotl (*Ambystoma velasci*) and anurans like *Rana moctezumae*; and reptiles, such as the aquatic snake (*Thamnophis eques*).

Although Carp-1 and Carp-2 were isolated, the capacity and extent to which these isolates could cause mortality to carps and other fish species within the Tecocomulco Lagoon are unknown. Taking into account existing Mexican regulations, the results of this study do not demonstrate whether the isolated virus meets Koch's postulates. Except for studies on parasitic helminths (Monks et al., 2013), to date no health studies exist for aquatic organisms in the Tecocomulco Lagoon, despite the existence of records on water-quality parameters (Aguilar-Martínez, 2007; Delgadillo, 2012),



**FIGURE 5** Phylogenetic tree for SVCV based on the obtained partial glycoprotein gene sequence, constructed using the neighbour-joining method. The values at the branches are bootstrap values with 1,000 replicates. The scale represents the evolutionary distance between two sequences. The accession number and origin of isolation are indicated for each isolate

algae (Novelo et al., 2005; Quiroz-Flores, Ramírez-García, & Lot-Helgueras, 2014), macroinvertebrate populations (Rico-Sánchez et al., 2014) and pesticide presence/levels (Aguilar-Martínez, 2007). Therefore, the impact of the isolated SVCV pathogen on fish populations in the Tecocomulco Lagoon remains unclear, and information regarding mortalities associated with this or prior cases is unavailable. This information gap could be due to the large size of the lagoon (1,769 ha; Rico-Sánchez et al., 2014) or, perhaps, due to the asymptomatic nature of affected fish, which act as SVCV carriers (Ahne et al., 2002). Furthermore, the lack of an active health-monitoring programme in Mexico (Ortega, 2012) and scarce knowledge of aquatic environments have conditioned local residents and fishermen to view low mortality rates as “normal,” without concerns for identifying the cause. In the present case, the responsible laboratory only received samples and notified the health authority of suspected SVCV.

In fact, only five of the 10 sampled fish evidenced classical clinical signs consistent with an SVCV infection, which is a notable finding to consider for future health and research assessments. The obtained results are similar to those described by Garver et al. (2007), who isolated SVCV from asymptomatic common carp in Lake Ontario (Canada). This correlates with observations that SVCV infection is mostly clinically inapparent (Ahne et al., 2002; OIE, 2017b). On the other hand, the clinical occurrence of an SVCV outbreak in goldfish specimens in a lake near Sao Paulo (Brazil) resulted in a 70% mortality rate (Alexandrino et al., 1998). In addition to the inherent difference of the involved infectious agents, variations in the manifested clinical signs, injuries and mortalities could be related to management practices and environmental conditions. In this case, it could be that the fish inhabited a large lagoon without spatial restrictions and with low stress. However, it is hard to calculate the impacts of several factors, including of fishing activities; sanitary and livestock drainage discharge; erosion; and the gradual extraction of water for farming, which results in new vegetation (Delgadillo, 2012). All of these factors could serve as environmental stressors that affect pathogenesis transmission and organism infection.

When and how the virus was introduced into the Tecocomulco Lagoon is unknown, but considering that between 1996 and 1997 the lagoon practically dried up, infection is likely a relatively recent occurrence. Also of possible relevance, this site is host to nearly 120 bird species, 78 of which are land species and 42 of which are aquatic species (Gobierno del estado de Hidalgo, 2003). Of the aquatic birds, 29 migrate from North America, where SVCV has been detected in wild (Garver et al., 2007) and farmed (OIE, 2017a) fish. It is important to underscore that the objective of this study is not to clarify the origin of the SVCV in fish from the Tecocomulco Lagoon, which, as a closed body of water, could mean a range of possibilities, such as the virus being introduced through carp stocking (a common practice in Mexico since the end of the 19th century; Tapia & Zambrano, 2003; Wakida-Kusunoki & Amador-del-Ángel, 2011); through migratory birds acting as viral vector carriers (Ahne et al., 2002); or even through the importation of ornamental fish, including different types of cyprinids, zebrafish and guppy (*Poecilia reticulata*; Zambrano

& Macías-García, 2000), which are species susceptible to or that act as carriers for SVCV (Ahne et al., 2002; Ashraf et al., 2016).

In any case, the occurrence of this case should alert health authorities to be on guard for other cases. For example, after the first SVCV outbreak at a koi farm in North America in 2002, eight subsequent SVCV detections or outbreaks have been recorded (Emmenegger et al., 2016). This exotic virus could, therefore, represent a potential threat to native and culture fish populations in Mexico. Further contributing to this potential threat is that one of the factors related to SVCV appearance is the temperature range in which fish live, with 10–17°C being optimum (Ahne et al., 2002). In Europe, the appearance of SVCV is related to temperature increases after winter. In the case of the Tecocomulco Lagoon, the water temperature fluctuates yearly between 13.1°C and 21.2°C (Delgadillo, 2012; Novelo et al., 2005; Quiroz-Flores et al., 2014); during the sampling period, the temperature range was closer to 13.1–15.1°C (Delgadillo, 2012).

Finally, sanitary diagnoses of wild fish are not mandatory in Mexico. This constitutes an inherent risk to the development of intensive farming of the common carp and other commercial species, such as rainbow trout or tilapia. Future surveillance of fish in the Tecocomulco Lagoon and other aquatic environments in the region will help to ascertain the prevalence, distribution and effects of SVCV pathogens on fish populations in Mexico.

## ACKNOWLEDGEMENTS


This work was supported by Grant FONDAP 15110027 and FONDECYT 1150695 from CONICYT, Chile, and Research Projects 4489/2018/CI from SIEA-UAEM and Ciencia Básica CONACYT-México: reference 287537.

## CONFLICT OF INTEREST

This research does not have conflict of interest.

## ORCID

Cesar Ortega  <https://orcid.org/0000-0003-4995-4676>

Ruben Avendaño-Herrera  <https://orcid.org/0000-0001-5368-4475>

## REFERENCES

- Afonso, C. L., Amarasinghe, G. K., Bányai, K., Bao, Y., Basler, C. F., Bavari, S., ... Kuhn, J. H. (2016). Taxonomy of the order *Mononegavirales*: Update 2016. *Archives of Virology*, 161, 2351–2360. <https://doi.org/10.1007/s00705-016-2880-1>
- Aguilar-Martínez, J. (2007). *Determinación de pesticidas organoclorados en Cyprinus carpio Linnaeus, 1758 del lago de Tecocomulco, Hidalgo*. Bachelor Dissertation, Universidad Autónoma del Estado de Hidalgo-UAEM, México.
- Ahne, W., Bjorklund, H. V., Essbauer, S., Fijan, N., Kurath, G., & Winton, J. R. (2002). Spring viremia of carp (SVC). *Diseases of Aquatic Organisms*, 52, 261–272. <https://doi.org/10.3354/dao052261>

- Alexandrino, A. C., Ranzani-Paiva, M. J. T., & Romano, L. A. (1998). Identificación de viremia primaveral de la carpa (VPC) *Carassius auratus* en San Pablo, Brasil. *Revista Ceres*, 45, 125–137.
- Ashraf, U., Lu, Y., Lin, L., Yuan, J., Wang, M., & Liu, X. (2016). Spring viraemia of carp virus: Recent advances. *Journal of General Virology*, 97, 1037–1051. <https://doi.org/10.1099/jgv.0.000436>
- CONAPESCA (2017). *Anuario estadístico de acuicultura y pesca 2017*. Comisión Nacional de Acuicultura y Pesca, Secretaría de Agricultura Ganadería Desarrollo Rural Pesca y Alimentación. Retrieved from [www.conapesca.gob.mx/work/sites/cona/dgppe/2017/ANUARIO\\_ESTADISTICO\\_2017.pdf](http://www.conapesca.gob.mx/work/sites/cona/dgppe/2017/ANUARIO_ESTADISTICO_2017.pdf) (accessed 10 October 2018).
- Delgadillo, A. (2012). *Determinación de parámetros fisicoquímicos, estado eutrófico y metales pesados de la laguna de Tecocomulco, Hidalgo; identificación de compuestos quelantes de Hydrocotyle ranunculoides L.f.* PhD Dissertation, Universidad Autónoma del Estado de Hidalgo, México.
- Emmenegger, E. J., Sanders, G. E., Conway, C. M., Binkowski, F. P., Winton, J. R., & Kurath, G. (2016). Experimental infection of six North American fish species with the North Carolina strain of spring Viremia of Carp Virus. *Aquaculture*, 450, 273–282. <https://doi.org/10.1016/j.aquaculture.2015.07.007>
- FAO (2018). *Cultured aquatic species information programme. Cyprinus carpio* (Linnaeus, 1758). Retrieved from [www.fao.org/fishery/culturedspecies/Cyprinus\\_carpio/en/](http://www.fao.org/fishery/culturedspecies/Cyprinus_carpio/en/) (accessed 27 May 2017).
- Fijan, N., Sulimanovic, D., Bearzotti, M., Muzinic, D., Zwillenberg, L. O., Chilmoneczyk, S., ... de Kinkelin, P. (1983). Some properties of the *Epithelioma papulosum cyprini* (EPC) cell line from carp *Cyprinus carpio*. *Annales De l'institut Pasteur/Virology*, 134, 207–220. [https://doi.org/10.1016/S0769-2617\(83\)80060-4](https://doi.org/10.1016/S0769-2617(83)80060-4)
- Gaafar, A. Y., Veselý, T., Nakai, T., El-Manakhly, E. M., Soliman, M. K., Soufy, H., ... Younes, A. (2011). Histopathological and ultrastructural study of experimental spring viraemia of carp (SVC) infection of common carp with comparison between different immunohistochemical techniques efficacy. *Life Sciences Journal*, 8, 523–533.
- Garver, K. A., Dwilow, A. G., Richard, J., Booth, T. F., Beniac, D. R., & Souter, B. W. (2007). First detection and confirmation of spring viraemia of carp virus in common carp, *Cyprinus carpio* L., from Hamilton Harbour, Lake Ontario, Canada. *Journal of Fish Diseases*, 30, 665–671. <https://doi.org/10.1111/j.1365-2761.2007.00851.x>
- Gobierno del estado de Hidalgo, Consejo Estatal de Ecología (2003). *Ficha Informativa de los Humedales de Ramsar: Laguna de Tecocomulco*. 29 de septiembre de 2003. Retrieved from [http://ramsar.conanp.gob.mx/docs/sitios/FIR\\_RAMSAR/Hidalgo/Laguna%20de%20Tecocomulco/LAGUNA\\_DE\\_TECOCOMULCO\\_FIR.pdf](http://ramsar.conanp.gob.mx/docs/sitios/FIR_RAMSAR/Hidalgo/Laguna%20de%20Tecocomulco/LAGUNA_DE_TECOCOMULCO_FIR.pdf) (accessed 28 March 2018).
- Goodwin, A. E. (2011). First report of spring viremia of carp virus (SVCV) in North America. *Journal of Aquatic Animal Health*, 14, 161–164. [https://doi.org/10.1577/1548-8667\(2002\)014<0161:FROSVO>2.0.CO;2](https://doi.org/10.1577/1548-8667(2002)014<0161:FROSVO>2.0.CO;2)
- Haghighi-Khiabani Asl, A., Bandehpour, M., Sharifnia, Z., & Kazemi, B. (2008). The first report of Spring Viraemia of carp in some rainbow trout propagation and breeding by pathology and molecular techniques in Iran. *Asian Journal of Animal and Veterinary Advances*, 3, 263–268. <https://doi.org/10.3923/ajava.2008.263.268>
- International Committee on Taxonomy of Viruses (ICTV) (2017). *Genus: Sprivirus*. Retrieved from [https://talk.ictvonline.org/ictv-reports/ictv\\_online\\_report/negative-sense-rna-viruses/mononegavirales/w/rhabdoviridae/800/genus-sprivirus](https://talk.ictvonline.org/ictv-reports/ictv_online_report/negative-sense-rna-viruses/mononegavirales/w/rhabdoviridae/800/genus-sprivirus) (accessed 20 November 2018).
- Kumar, S., Stecher, G., & Tamura, K. (2016). MEGA7: Molecular evolutionary genetics analysis version 7.0 for bigger datasets. *Molecular Biology and Evolution*, 33, 1870–1874. <https://doi.org/10.1093/molbev/msw054>
- López-Jiménez, S. (1987). Enfermedades más frecuentes de las carpas cultivadas en México. *Acuavisión Revista Mexicana De Acuicultura*, 9, 11–13.
- Miller, O., Fuller, F. J., Gebreyes, W. A., Lewbart, G. A., Shchelkunov, I. S., Shivappa, R. B., ... Dixon, P. F. (2007). Phylogenetic analysis of spring viremia of carp virus reveals distinct subgroups with common origins for recent isolates in North America and the UK. *Diseases of Aquatic Organisms*, 76, 193–204. <https://doi.org/10.3354/dao076193>
- Monks, S., Pulido-Flores, G., Bautista-Hernández, C. E., Alemán-García, B., Falcón Ordaz, J., & Gaytán-Oyarzún, J. C. (2013). El uso de helmintos parásitos como bioindicadores en la evaluación de la calidad del agua: Lago de Tecocomulco vs. Laguna de Metztlán, Hidalgo, México. In G. Pulido-Flores, & S. Monks (Eds.), *Estudios científicos en el estado de Hidalgo y zonas aledañas* (Vol. II, pp. 25–34). Lincoln, NE: Zea Books. Retrieved from <http://digitalcommons.unl.edu/hidalgo/6>
- Negele, R. D. (1977). Histopathological changes in some organs of experimentally infected carp fingerlings with Rhabdovirus carpio. *Bulletin De L'office International Des Épidémiologies*, 87, 449–450.
- Novelo, E., Montejano, G., Cantoral, E., & Tavera, R. (2005). Las Algas de la Laguna de Tecocomulco. In R. Huízar, E. Jiménez, & C. Juárez (Eds.), *La Laguna de Tecocomulco, Geo-Ecología de un Desastre* (pp. 131–140). México: Publicación Especial 3, Instituto de Geología, UNAM.
- OIE (World Organization for Animal Health) (2017a). *Spring viraemia of carp*. Aquatic Animal Health. Retrieved from [www.oie.int/en/standard-setting/aquatic-code/access-online/?htmfile=chapitre\\_svc.htm](http://www.oie.int/en/standard-setting/aquatic-code/access-online/?htmfile=chapitre_svc.htm) (accessed 18 January 2018).
- OIE (World Organization for Animal Health) (2017b). *Manual of diagnostic tests for aquatic animals*. Retrieved from [www.oie.int/international-standard-setting/aquatic-manual/](http://www.oie.int/international-standard-setting/aquatic-manual/) (accessed 18 January 2018).
- Ortega, C. (2012). Veterinary medical education and veterinary involvement in aquatic animal health and aquaculture in Mexico. *Journal of Veterinary Medical Education*, 39(2), 195–199. <https://doi.org/10.3138/jvme.0811.082R>
- Ortega, C., Mancera, G., Enríquez, R., Vargas, A., Martínez, S., Fajardo, R., ... Romero, A. (2016). First identification of *Francisella noatunensis* subsp. *orientalis* causing mortality in Mexican tilapia *Oreochromis* spp. *Diseases of Aquatic Organisms*, 120, 205–215. <https://doi.org/10.3354/dao02999>
- Quiroz-Flores, A., Ramírez-García, P., & Lot-Helgueras, A. (2014). Variación anual de la biomasa de *Nymphoides fallax ornduff* (menyanthaceae) en la laguna de Tecocomulco, Hidalgo, México. *Polibotánica*, 37, 93–108.
- Rico-Sánchez, A., Rodríguez-Romero, A., López-López, E., & Sedeño-Díaz, J. (2014). Patrones de variación espacial y temporal de los macroinvertebrados acuáticos en la Laguna de Tecocomulco, Hidalgo (México). *Revista De Biología Tropical*, 62, 81–96. <https://doi.org/10.15517/rbt.v62i0.15780>
- Soriano-Vargas, E., Castro-Escarpullí, G., Aguilera-Arreola, M. G., Vega-Castillo, F., & Salgado-Miranda, C. (2010). Isolation and identification of *Aeromonas bestiarum* in cultured common carp (*Cyprinus carpio* L.) from Santa Maria Chapa de Mota, Estado de Mexico, Mexico. *Veterinaria México*, 41, 111–115.
- Stone, D. M., Ahne, W., Denham, K. L., Dixon, P. F., Liu, C. T., Sheppard, A. M., ... Way, K. (2003). Nucleotide sequence analysis of the glycoprotein gene of putative spring viraemia of carp virus and pike fry rhabdovirus isolates reveals four genogroups. *Diseases of Aquatic Organisms*, 53, 203–210. <https://doi.org/10.3354/dao053203>
- Tapia, M., & Zambrano, L. (2003). From aquaculture goal to real social and ecological impacts: Carp introduction in rural central Mexico. *Ambio*, 32, 252–257.
- Vélez-Hernández, E. M., Constantino-Casas, F., García-Márquez, L. J., & Osorio-Sarabia, D. (1998). Gill lesions in common carp, *Cyprinus carpio* L., in Mexico due to the *Metacercariae* of *Centrocestus formosanus*. *Journal of Fish Diseases*, 21, 229–232. <https://doi.org/10.1046/j.1365-2761.1998.00091.x>



- Wakida-Kusunoki, A. T., & Amador-del-Ángel, L. E. (2011). First record of the common carp *Cyprinus carpio* var. *communis* (Linnaeus, 1758) and the mirror carp *Cyprinus carpio* var. *specularis* (Lacepède, 1803) in Tabasco. *Southern Gulf of Mexico. Aquatic Invasions*, 6, 557–560. <https://doi.org/10.3391/ai.2011.6.S1.013>
- Zambrano, L., & Macías-García, C. (2000). Impact of introduced fish for aqua-culture in Mexican freshwater systems. In R. Claudi, & J. H. Leach (Eds.), *Non-indigenous freshwater organisms* (pp. 113–124). Boca Raton, FL: Lewis Publishers.

**How to cite this article:** Ortega C, Cañas-Lopez L, Irgang R, et al. First detection of spring viraemia of carp virus in common carp (*Cyprinus carpio* L.) affected by a septicaemic disease in Mexico. *J Fish Dis.* 2019;00:1–9. <https://doi.org/10.1111/jfd.12969>